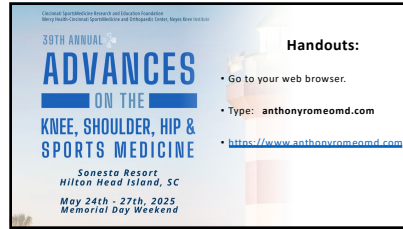
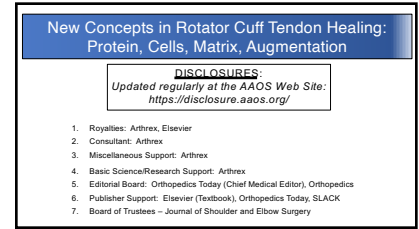


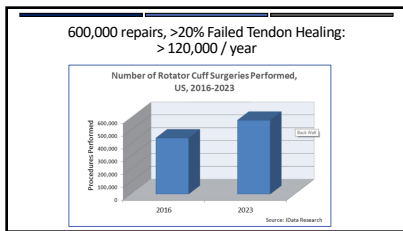
1



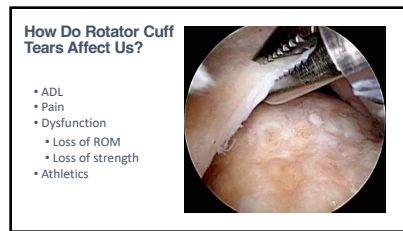
2



3



5



7

Copyright 1991 by The Journal of Bone and Joint Surgery, Incorporated

1991 Repairs of the Rotator Cuff

CORRELATION OF FUNCTIONAL RESULTS WITH INTEGRITY OF THE CUFF*

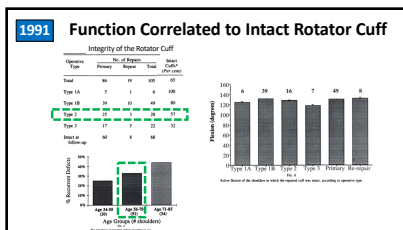
BY DOUGLAS T. HARRYMAN, II, M.D.,¹ LAURENCE A. NACK, M.D.,² KEITH Y. WANG, M.D.,³ SARAH E. JACKINS, R.P.T.,⁴ MICHAEL L. BETHARRISON, M.D.,⁵ AND FREDERICK A. MATTHEW, III, M.D.,⁶ SEATTLE, WASHINGTON

From the Shoulder and Elbow Service, Department of Orthopaedics, University of Washington, Seattle

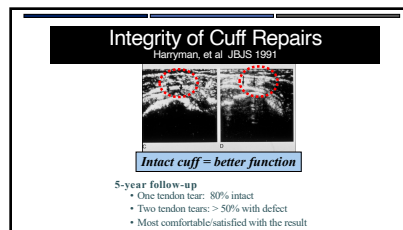
FUNCTIONAL RESULTS ACCORDING TO OPERATIVE TYPE

Operative Type	No. of Shoulders	Age at Repair* (Yrs.)	Flexion†	Average Active Motion at the Time of Follow-up (Degrees)		
				External Rotation	Internal Rotation	at 0 Degrees of Abduction
Type 1A	6	49 ± 13	126	36	48	78
Type 1B	49	57 ± 8	129	40	70	77
Type 2	28	64 ± 6	119	28	60	74
Type 3	22	64 ± 6	93	31	60	70

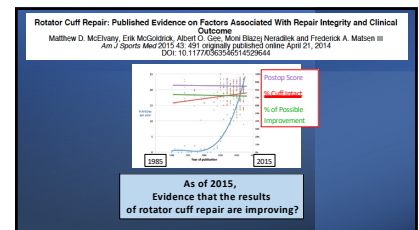
8



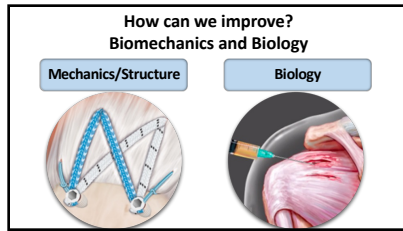
9



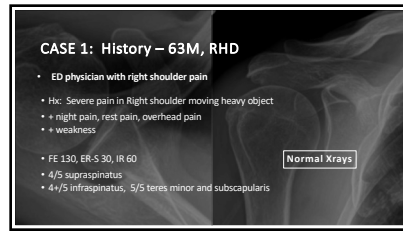
10



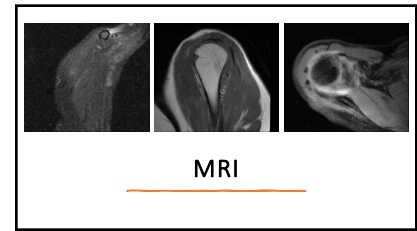
11



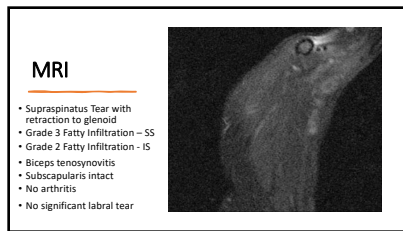12



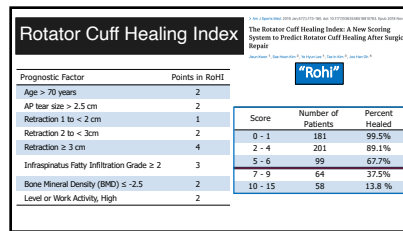
13




14



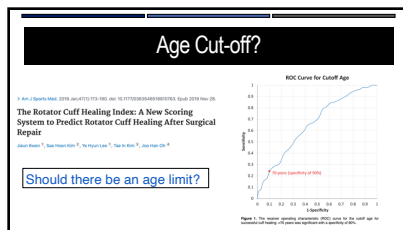
15



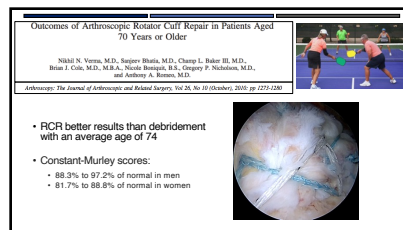
16



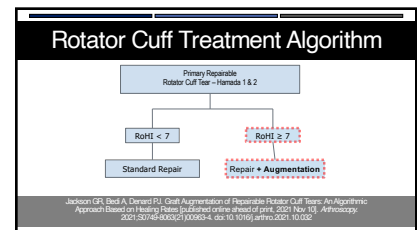
17



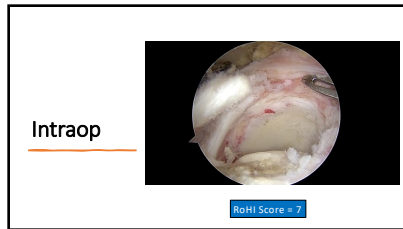18



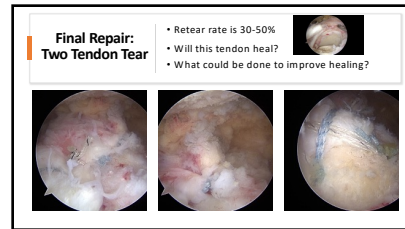
19



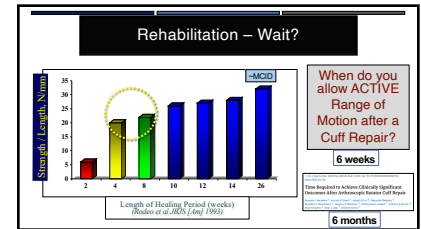
20



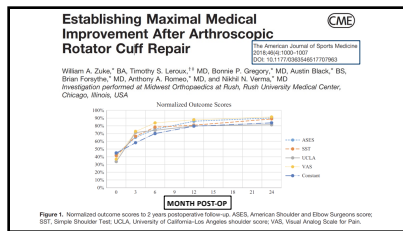
21



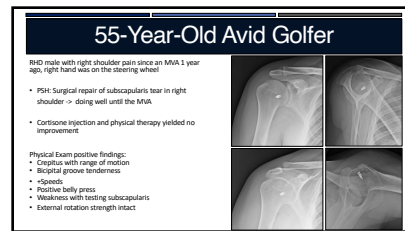
22



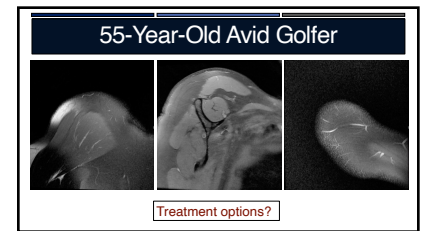
23



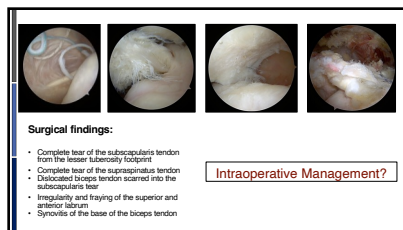
24



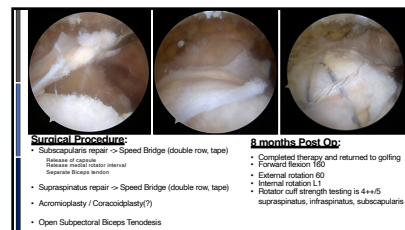
25



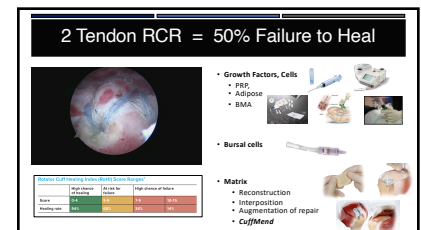
26



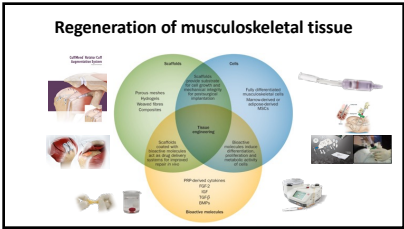
27



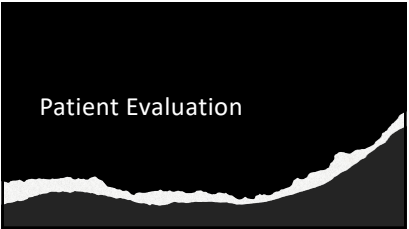28



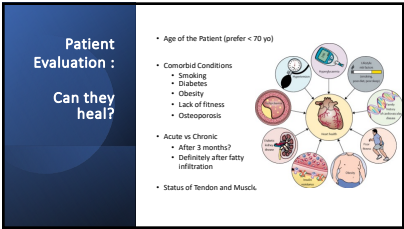
29



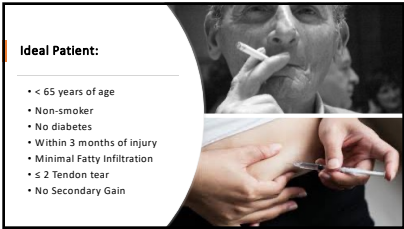
30



35



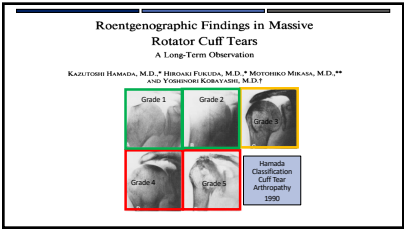
36



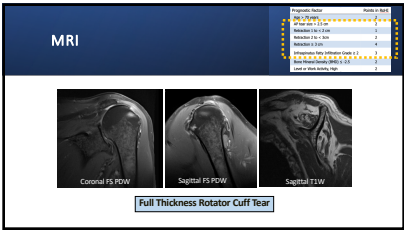
39



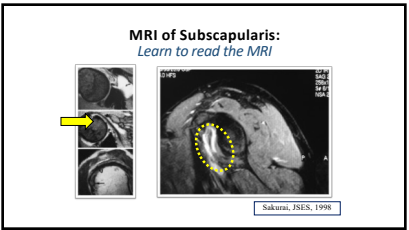
43




44



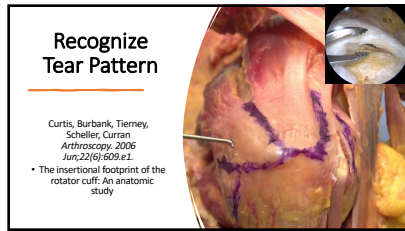
45



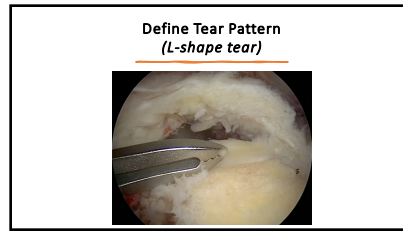
46



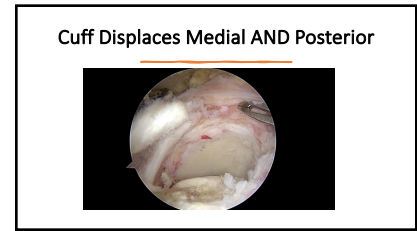
55




56




57




58



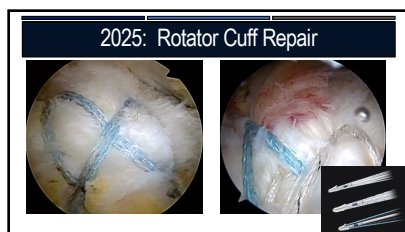
61



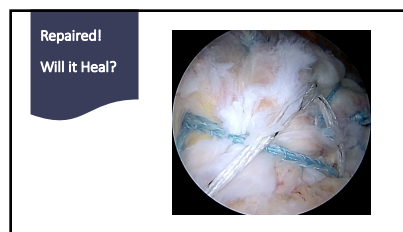
62



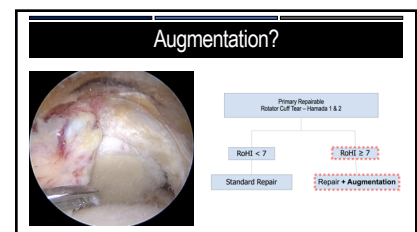
63



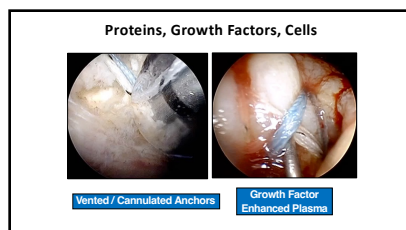
66



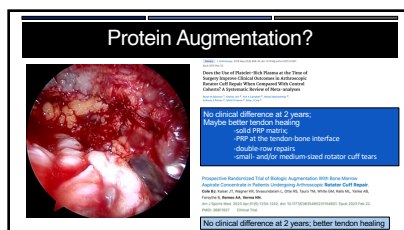
67



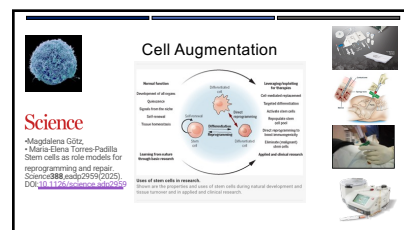
72



73



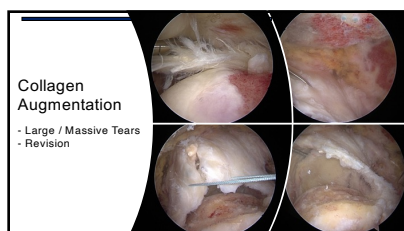
74



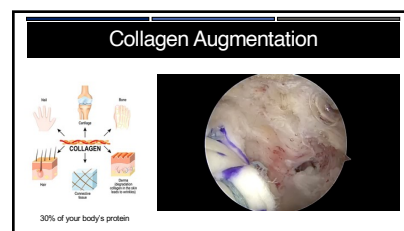
75



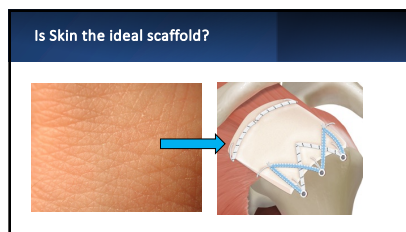
76



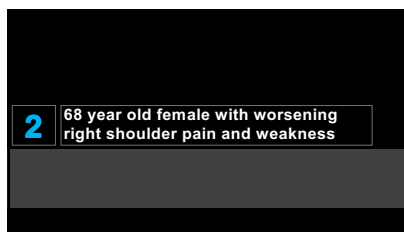
77



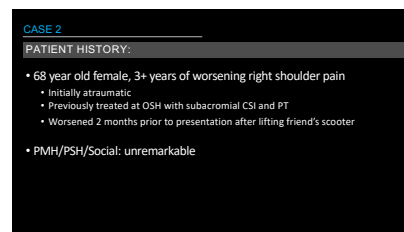
78



79



80



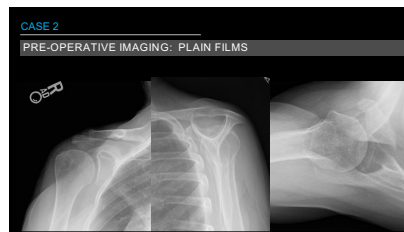
81

CASE 2

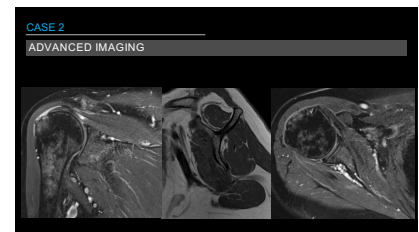
PHYSICAL EXAM:

- BMI 26
- Normal C-spine ROM
- No scapular dyskinesis
- Active ROM:** FF 150, ABD 90 (limited by pain), ER-S 60, ER-ABD 70, IR to lumbar spine
- Strength:** 4/5 FF, 4/5 ER-S, 5/5 IR, negative belly-press & lift-off
- Biceps:** TTP biceps groove, positive Speeds

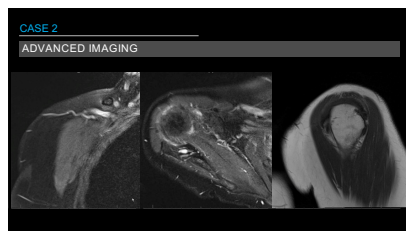
82




83



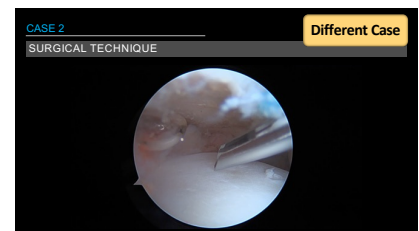84



85



88



89

CASE 2

POST-OPERATIVE COURSE

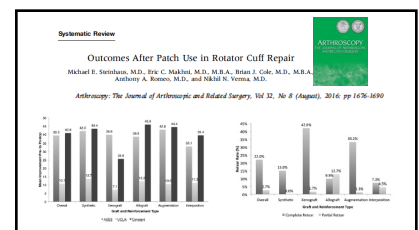
- 6 weeks sling
- Active-Assist ROM at 2 weeks
- Strengthening at 10-12 weeks
- RTS at 6-9 months

90

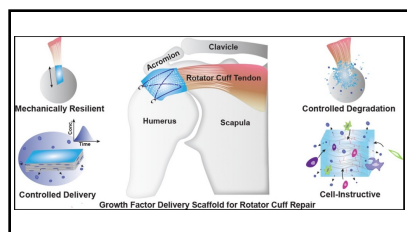
Porous "Bio-Inductive" Implant

- Implant derived from bovine Achilles tendon, highly purified, highly porous, highly oriented design (Xenograft)
- Bioinductive Implant gradually absorbs within six months, leaving a layer of new "tendon-like" tissue to biologically augment the existing tendon

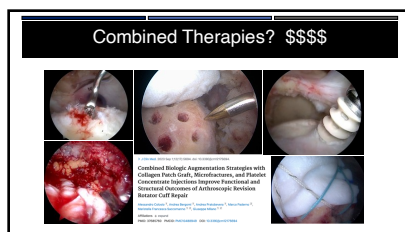91



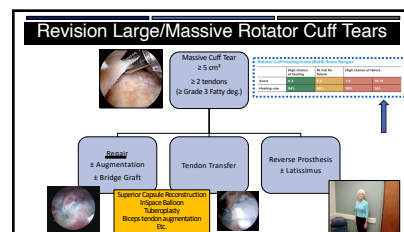
92



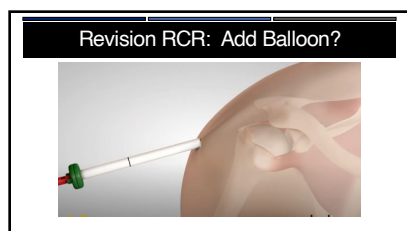
93



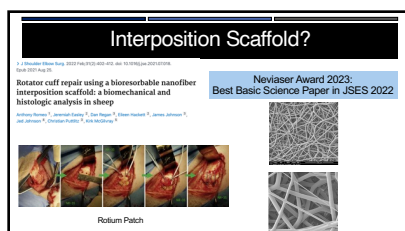
94



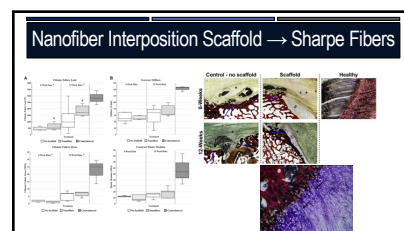
95



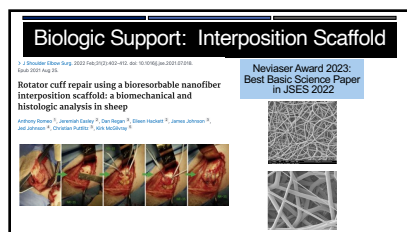
96



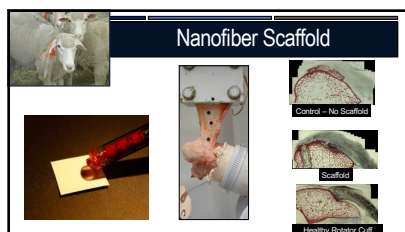
97




98



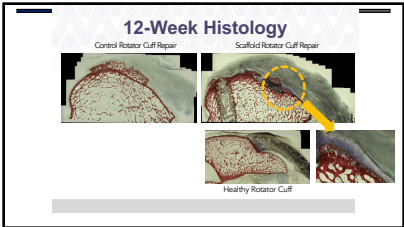
99



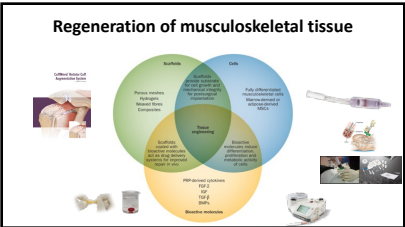
100



101



102




104

5 Key Areas to Improve Tendon Healing

1. Patient Assessment
2. Surgical Preparation of Repair
3. Surgical Technique
4. Biologic Augmentation
5. Postoperative Rehabilitation

This slide lists five key areas to improve tendon healing. To the right of the list are several small images: a photograph of a surgical site, a diagram of a joint, and a series of small circular icons representing different stages or components of the healing process.

105



106