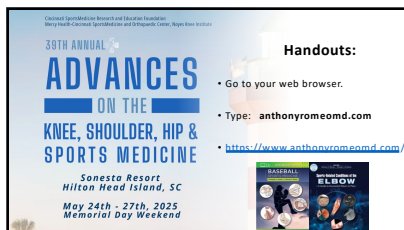
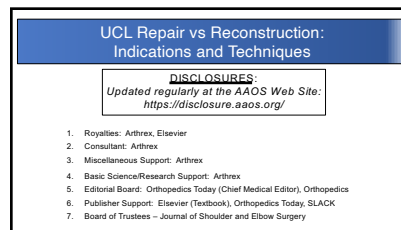




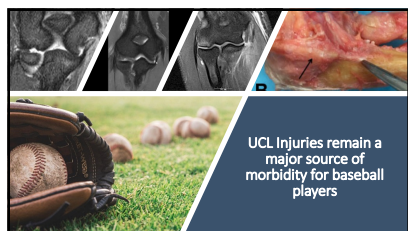
1



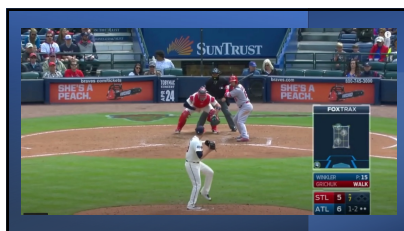2



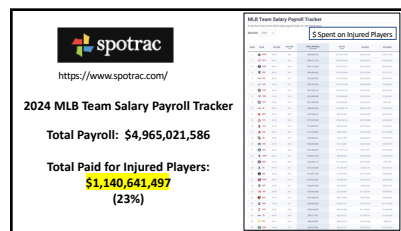
3



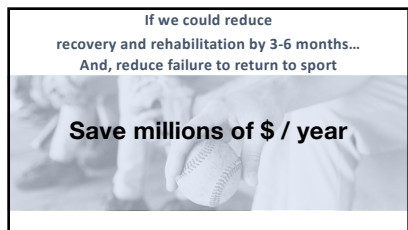4




5




6




7



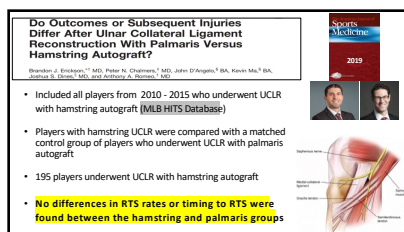
8




9



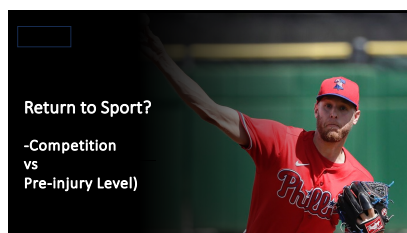
10




11



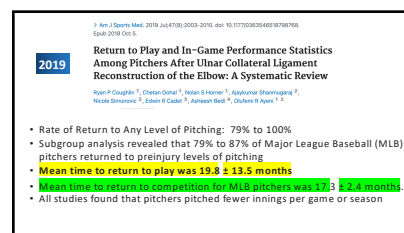
12



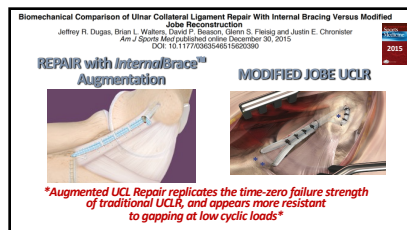
13



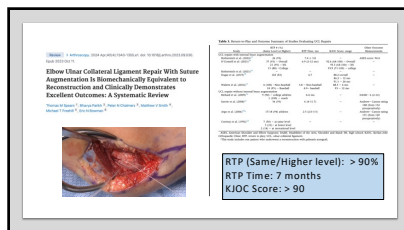
14



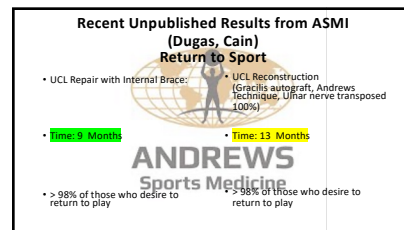
15



16

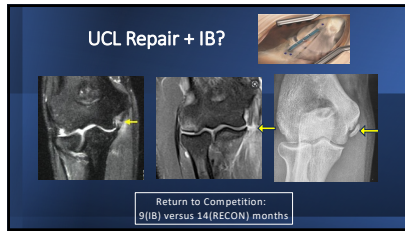


17

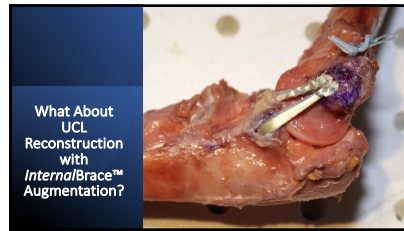

18

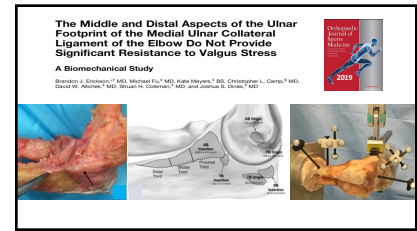




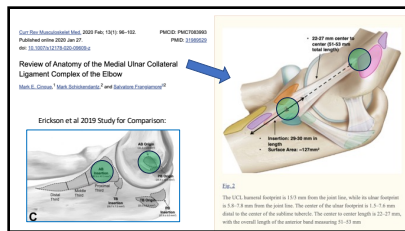
28



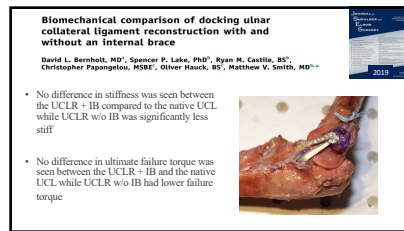
29



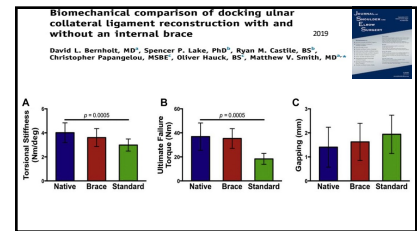
30



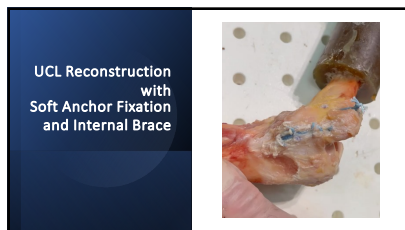
31



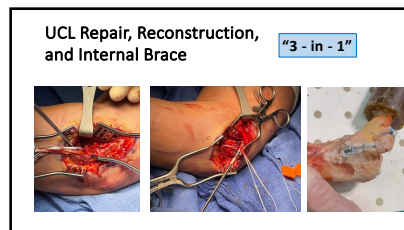
32



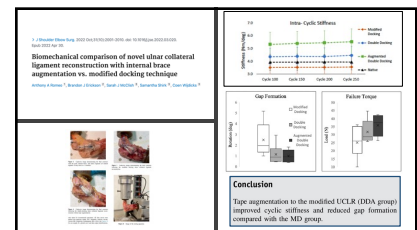
33



34



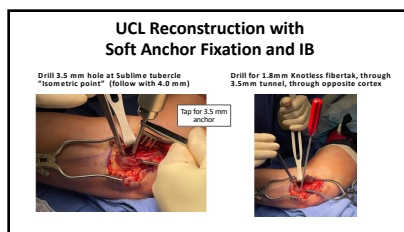
35



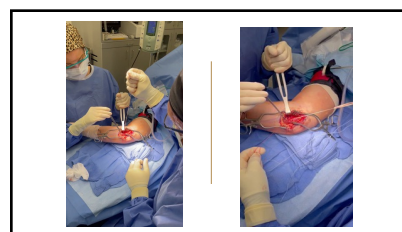
36



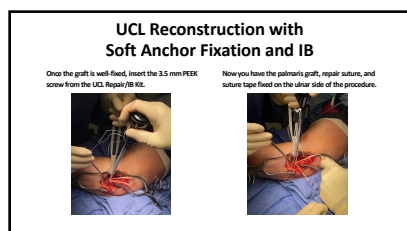
37



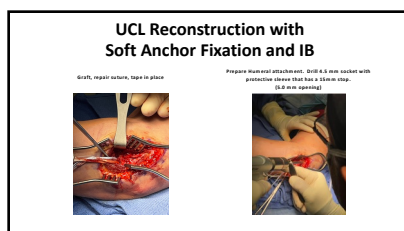
38



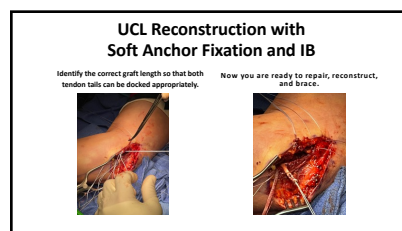
39



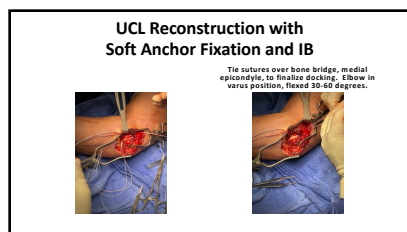
40



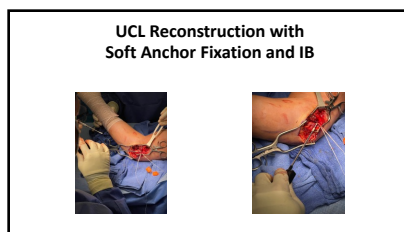
41



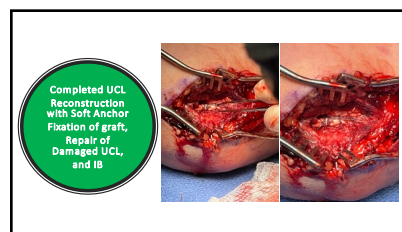
42



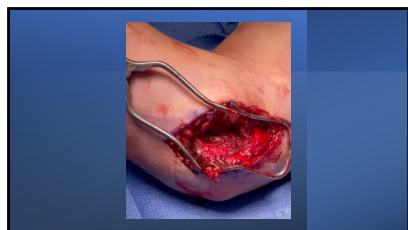43



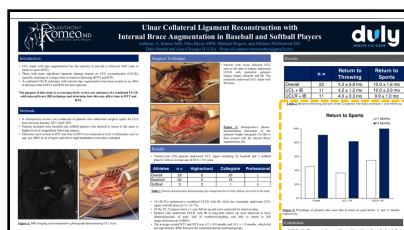
44



45



46



47

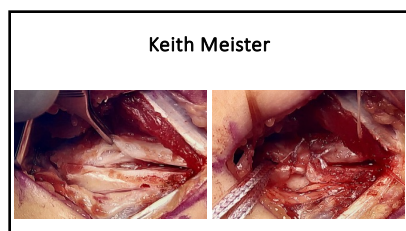
Keith Meister

Hybrid?

Keith, good luck tonight! Wishing your team the best! I know that you have been using a hybrid method for UCL surgery: your classic tendon procedure with an ulna tunnel and docking on the humerus, combined with some form of internal brace. Can you share with me a picture or figure of that procedure?

Have over 300 I think like this. Prob 200 pro elbows. Happy to discuss...

48



49

Ulnar Side (Sublime Tubercle)

Keith Meister

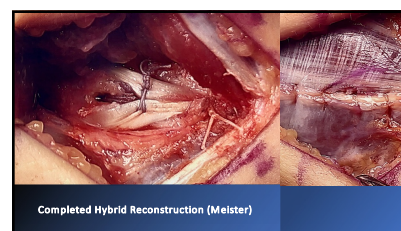
Everything docked proximally. I never use a screw proximally.

Tension at 30 deg flexion full supination and tie down tight.

Tension brace first then graft.

- Graft through tunnel
- IB fixed with Anchor at Separate Site

50



51

UCL – to repair, reconstruct, or both?


First Choice:
Repair with Internal Brace:
Younger athlete
Discontinuous injury
No loss of tissue
No heterotopic bone
Desire to return in 6-9 months

Second Choice:
Reconstruction with autograft:
Significant damage to ligament
Heterotopic bone
Ability to rehab over 12-18 months

Third Choice:
Repair, Reconstruction, Internal Brace:
Tissue deficiency
Desire to return 9-12 months

?

54



55



56